

# Maxillary Case Study

Michael J. Sillers, MD  
Birmingham, AL

## *Relieva Balloon Sinuplasty™* Devices Used:

*Relieva* Sinus Balloon Catheter (5x16mm)  
*Relieva* Sinus Guide Catheter (M-90)  
Standard *Relieva* Sinus Guidewire (0.035")  
*Relieva* Sinus Lavage Catheter  
*Relieva* Sinus Balloon Inflation Device

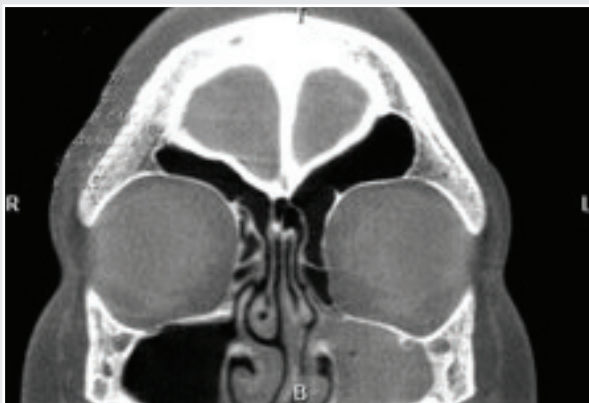

FIGURE 1

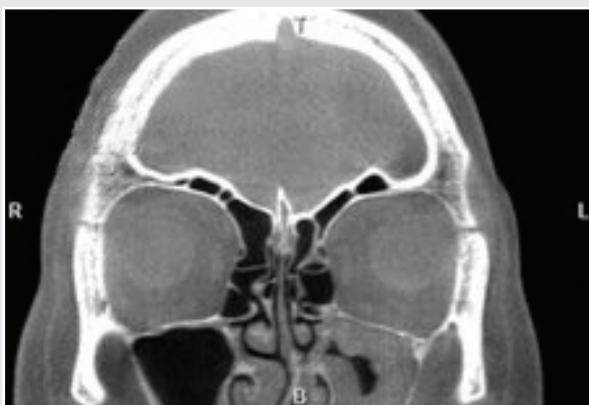


FIGURE 2

## Background

This patient is an 18 year-old male student who was referred to Dr. Sillers. He suffered from chronic rhinosinusitis which had notably worsened over the past year. Despite multiple appropriate and prolonged courses of antibiotics, he reported continued rhinorrhea, yellow PND, a bronchitis-type cough, and pulmonary symptoms for which he used nebulized Albuterol. Recent allergy testing revealed positive reactions to animals, trees, and grasses. Current medications included Singulair®, Flonase®, Amoxicillin, and Albuterol. Diagnostic nasal endoscopy revealed a deviated nasal septum to the left with sharp spur impacting the lateral nasal wall. The CT scan confirmed the septal deviation and revealed isolated left maxillary sinus disease (Figures 1 and 2). Based on the nature of his disease and his anatomical characteristics, it was determined that this patient would undergo endoscopic sinus surgery to include a septoplasty and the use of the *Relieva Balloon Sinuplasty™* devices.

## Treatment

Septoplasty and endoscopic left maxillary antrostomy using balloon dilation technique were performed under general anesthesia. The septoplasty was performed first in a standard fashion. Attention was then turned to the lateral nasal wall. Using zero and 45 degree telescopes for visualization, the uncinat process was fractured medially using a maxillary ostium seeker, but not removed. Using a *Relieva* Sinus Guide Catheter (M-90), a standard *Relieva* Sinus Guidewire (0.035") was placed through the left maxillary ostium into the maxillary sinus. After the position of the Sinus Guidewire was verified fluoroscopically, a 5x16mm *Relieva* Sinus Balloon Catheter (5x16mm) was passed over the Sinus Guidewire into the maxillary sinus. The position was confirmed with fluoroscopy. The sinus balloon was inflated to 8 atm pressure, deflated, and removed. The *Relieva* Sinus Lavage Catheter was then passed over the Sinus Guidewire, into the left maxillary sinus, and its position was verified fluoroscopically. 50cc of saline were used to irrigate the left maxillary sinus. The Sinus Lavage Catheter and Sinus Guide Catheter were removed and the nasal cavity was suctioned. There was minimal bleeding and no packing was required. The patient was extubated and taken to the recovery room in satisfactory condition.

# Maxillary Case Study

Continued

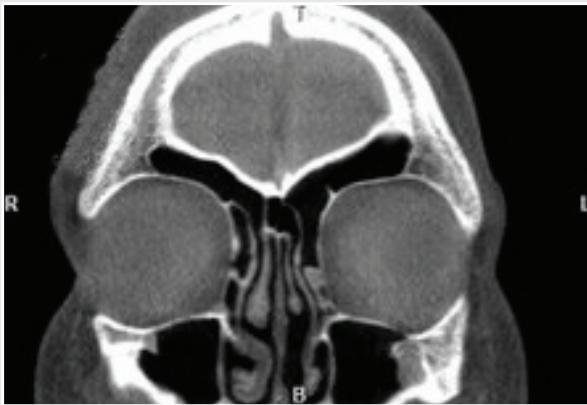

FIGURE 3

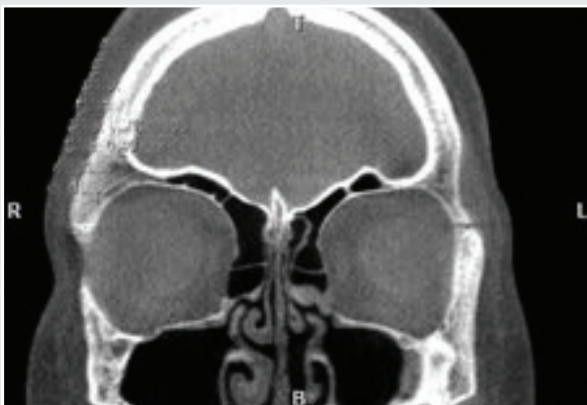

FIGURE 4

## Discussion

At his one-week postoperative visit, the patient reported feeling stuffy, but otherwise was without complaints. Specifically he denied significant bleeding. Diagnostic nasal endoscopy was performed with a rigid scope. The septum was intact and midline. There was minimal non-purulent mucous in the left maxillary infundibulum and the uncinates were medialized.

Non-contrast CT scan of the paranasal sinuses (Figures 3 and 4) showed a midline nasal septum, medialized uncinates, patent maxillary infundibulum, and near-complete resolution of the maxillary sinus mucosal thickening. This patient tolerated the procedure extremely well and continued to do well post-operatively. Although the patient arrived in the surgeon's office requesting the *Balloon Sinuplasty*™ devices, it was the after surgical assessment that proved these devices would be appropriate to use during his surgery. The patient recently completed his 2 month post-op follow up appointment and continues to be asymptomatic.

**Acclarent, Inc.**  
1525-B O'Brien Drive  
Menlo Park, CA 94025 U.S.A.

Toll Free: 1-877-SPLASTY  
(1-877-775-2789)  
Main: 1-650-687-5888

Fax: 1-650-687-5889  
Email: [info@acclarent.com](mailto:info@acclarent.com)  
[www.acclarent.com](http://www.acclarent.com)

**Acclarent**™  
The clear choice.

©2006-2008 Acclarent, Inc. All rights reserved. Acclarent, *Balloon Sinuplasty*, and *Relieva* are trademarks of Acclarent, Inc. MKT00792 Rev. D

Singulair is a product and registered trademark of Merck & Co., Inc.  
Flonase is a product and registered trademark of GlaxoSmithKline.